



RESENTING CLINICAL SIGNS

History: Presented on 12/3/21 for an acute episode of collapse. Has experienced several other episodes recently. They last ~45 seconds to 1 minute, and are usually preceded by coughing. No murmur or arrhythmia on exam.

DATE

12/23/21

ECHOCARDIOGRAPHIC FINDINGS

2D, M-mode, and Doppler study.

PERFORMED BY:

Dr. Jacquie Pankatz

Left atrial size is normal. The mitral valve is normal. Left ventricular dimensions are normal. Left ventricular systolic function is normal. The aorta and aortic valve are normal. Right atrial and right ventricular dimensions are normal. The tricuspid valve is normal. The pulmonary artery and pulmonic valve are normal. No shunting lesions are visualized. No pericardial effusion or cardiac masses are seen.

INTERPRETED BY

Keith Blass, DVM,
MS, DACVIM
(Cardiology)

LVIDd - 33.3 mm
LVIDs - 23.3 mm
FS - 30%
LVOT - 1.25 m/s
RVOT - 0.80 m/s

PATIENT

Jessie Smallwood

ASSESSMENT/RECOMMENDATIONS

Normal echocardiogram

SPECIES

Canine

This examination demonstrates no evidence of structural heart disease. As such, no reason for Jessie's collapsing episodes is appreciated in the image set. Given the temporal association between coughing and collapse, it's possible that Jessie could be experiencing "cough drop", which is a form of vasovagal syncope, though other types of vasovagal syncope and an intermittent arrhythmia should also be considered as possible causes.

BREED

Vizsla

An ECG is recommended to evaluate for the presence of an obvious arrhythmia. An event monitor may be warranted if Jessie continues to experience collapsing episodes.

SEX

FS

No therapy is recommended based on Jessie's echocardiogram. Should cough drop be present, elimination of the cough should resolve Jessie's collapsing episodes.

A recheck echocardiogram is recommended if new physical exam and/or clinical abnormalities suggestive of the presence of structural heart disease develop.

AGE

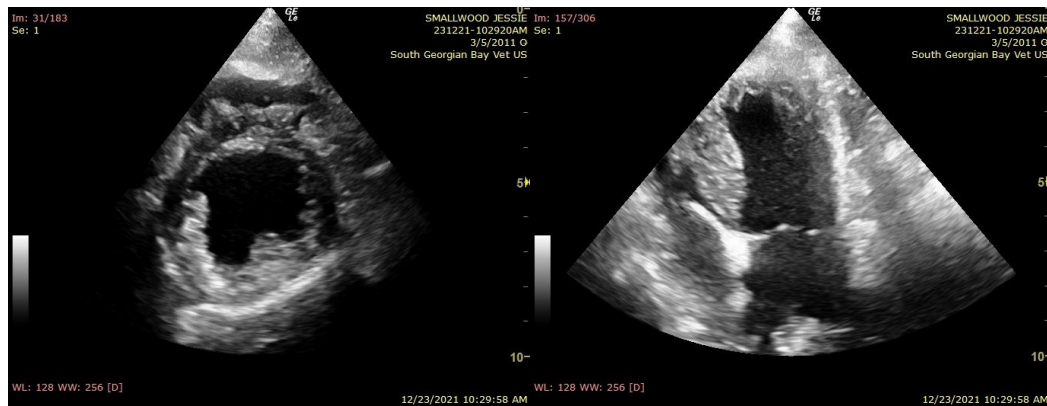10 y

WEIGHT

22.1 lb

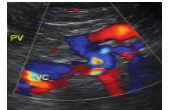
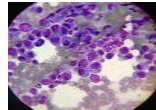
HOSPITAL NAME

Mountain Vista VH



REFERRING VET

Dr. Pankatz



The information and recommendations provided are based on the images presented by the referring veterinarian. No evaluation can be communicated regarding pathology that was not visible in the image/video clips provided.

DATE

12/23/21

Thank you for this referral. If the clinical or image interpretation does not parallel your findings or if I can be of any further assistance please contact me.

PERFORMED BY:

Dr. Jacquie Pankatz

Keith Blass, DVM, MS, DACVIM (Cardiology)
KeithBlass@gmail.com
631-804-5754

INTERPRETED BY

Keith Blass, DVM,
MS, DACVIM
(Cardiology)

PATIENT

Jessie Smallwood

SPECIES

Canine

BREED

Vizsla

SEX

FS

AGE

10 y

WEIGHT

22.1 lb

HOSPITAL NAME

Mountain Vista VH

REFERRING VET

Dr. Pankatz